

Marking Axillary Lymph Nodes With Radioactive Iodine Seeds for Axillary Staging After Neoadjuvant Systemic Treatment in Breast Cancer Patients

The MARI Procedure

Mila Donker, MD,* Marieke E. Straver, MD, PhD,* Jelle Wesseling, MD, PhD,† Claudette E. Loo, MD,‡ Margaret Schot,§ Caroline A. Drukker, MD,* Harm van Tinteren, PhD,¶ Gabe S. Sonke, MD, PhD,§ Emiel J. Th. Rutgers, MD, PhD,* and Marie-Jeanne T. F. D. Vrancken Peeters, MD, PhD*

Objective: The MARI procedure [marking the axillary lymph node with radioactive iodine (^{125}I) seeds] is a new minimal invasive method to assess the pathological response of nodal metastases after neoadjuvant systemic treatment (NST) in patients with breast cancer. This method allows axilla-conserving surgery in patients responding well to NST.

Methods: Prior to NST, proven tumor-positive axillary lymph nodes were marked with a ^{125}I seed. This marked lymph node is the so-called MARI-node. After NST, the MARI node was selectively removed using a γ -detection probe. A complementary axillary lymph node dissection was performed in all patients to assess whether pathological response in the MARI node was indicative for the pathological response in the additional lymph nodes.

Results: A tumor-positive axillary lymph node was marked with a ^{125}I seed in 100 patients. The MARI node was successfully identified in 97 of these 100 patients (identification rate 97%). Two patients did not undergo subsequent axillary lymph node dissection, leaving 95 patients for further analysis. The MARI node contained residual tumor cells in 65 of these 95 patients. In the other 30 patients, the MARI node was free of tumor, but additional positive lymph nodes were found in 5 patients. Thus, the MARI procedure correctly identified 65 of 70 patients with residual axillary tumor activity (false negative rate $5/70 = 7\%$).

Conclusions: This study shows that marking and selectively removing metastatic lymph nodes after neoadjuvant systemic treatment has a high identification rate and a low false negative rate. The tumor response in the marked lymph node may be used to tailor further axillary treatment after NST.

Keywords: axilla, breast cancer, iodine seed, neoadjuvant systemic treatment, staging

(*Ann Surg* 2015;261:378–382)

Neoadjuvant or primary systemic treatment is increasingly applied in the treatment of operable breast cancer. Down staging of the primary tumor is one of the important goals of neoadjuvant systemic treatment (NST), thereby permitting breast-conserving treatment without affecting the risk for a local relapse.^{1–6} Complete pathological response rates after NST vary across histological sub-

types and can be more than 50% in HER2-positive disease. Down staging of the axilla is also observed in patients initially presenting with metastatic lymph nodes. Complete pathological response rates in the axilla vary between 22% and 42% in reported series, again depending on tumor subtype.^{7,8}

The therapeutic effect of a complete axillary lymph node dissection (ALND) is limited in case of a complete pathologic response in the axilla. If reliably identified, such patients can be offered a more conservative therapy of the axilla, sparing them the substantial short- and long-term morbidity of an ALND.^{9,10} Physical examination and imaging such as ultrasonography or positron emission tomography-computed tomography have insufficient sensitivity and specificity to discriminate between residual disease and a complete pathological response in the axilla.^{11–13} Postchemotherapy sentinel node (SN) biopsy (SNB) in patients with proven metastatic lymph nodes before NST is under debate, because different rates of identification rates (between 68% and 100%) and false-negative rates (between 5% and 30%) are reported.^{14,15} In many of the studies described, the presence of nodal metastasis before the NST was a predictive factor for failure of the SNB.

We aimed to develop a new technique to assess the response to NST in patients presenting with nodal metastasis. For this purpose, radioactive iodine (^{125}I) seeds were used. The use of ^{125}I seeds is increasingly applied in breast-conserving surgery.^{16,17} Recent studies have described the use of ^{125}I seed localization to facilitate breast-conserving surgery also after NST.^{18,19} Before the start of systemic treatment, a ^{125}I seed is placed in the center of the tumor. In case of a good clinical response after systemic treatment, a local excision can be performed around the ^{125}I seed to remove residual disease or confirm the complete response by histological examination.

^{125}I seed localization can also be performed in lymph nodes. It has previously been shown in a feasibility study with 15 patients that it is technically possible to mark tumor-positive axillary lymph nodes with a ^{125}I seed before NST and selectively remove them afterward: the “Marking Axillary Lymph Nodes With Radioactive Iodine ^{125}I Seeds” (MARI) procedure.²⁰ In this report, the final analysis of the predictive value of this novel surgical technique to identify residual axillary lymph node metastasis in a prospective study is presented.

METHODS

Patients and Systemic Treatment Regimens

From October 2008 until November 2012, patients with proven axillary lymph node metastases who were scheduled to undergo NST were asked to participate in this study. A total of 103 patients agreed and signed informed consent. Before the start of neoadjuvant treatment, tumor size was assessed with magnetic resonance imaging, and biopsies of the breast tumor were performed to determine the

From the Departments of *Surgical Oncology; †Pathology; ‡Radiology; §Medical Oncology; and ¶Statistics, Netherlands Cancer Institute-Antoni van Leeuwenhoek Hospital, Amsterdam, The Netherlands.

Disclosure: The authors declare no conflicts of interest.

Reprints: Marie-Jeanne T. F. D. Vrancken Peeters, MD, PhD, Department of Surgical Oncology, Netherlands Cancer Institute-Antoni van Leeuwenhoek Hospital, Plesmanlaan 121, NL-1066 CX, Amsterdam, The Netherlands. E-mail: m.vrancken@nki.nl.

Copyright © 2014 Wolters Kluwer Health, Inc. All rights reserved.

ISSN: 0003-4932/14/26102-0378

DOI: 10.1097/SLA.0000000000000558

histological subtype and receptor status. Axillary staging was performed with ultrasonography and in suspect lymph nodes, fine-needle aspiration cytology was performed. Tumors were classified according to the standard criteria of the World Health Organization, and the NST regimen depended on the presence or absence of HER2 amplification (Table 1).²¹

The institutional ethical committee approved this study. Adjuvant radiotherapy and systemic treatment were given according to Dutch national guidelines.

Seed Localization

A detailed overview of the MARI procedure was given previously.²⁰ A titanium encapsulated ¹²⁵I seed (STM1251, Bard Brachytherapy Inc., Carol Stream, IL) with an average energy of 27 keV and a half-life time of 59.6 days was placed in an 18-gauge needle. Under ultrasound guidance, the ¹²⁵I seed was placed in a previous proven metastatic lymph node by 1 of 15 different radiologists (Figs. 1A, B). This marked lymph node is further referred to as the MARI node. At the moment of the implantation, the ¹²⁵I seeds had an apparent activity varying from 0.04 to 0.19 mCi (1.6–7.0 MBq) and the dose rate constant is 1.018 cGy h⁻¹U⁻¹. Although the dose of the ¹²⁵I seeds used for localization of metastatic lymph nodes is low, it requires authorization by the Dutch government. Furthermore, some safety issues need to be addressed. Radiation safety protocols and detailed documentation regarding the acquisition, handling, and storage including guidelines for patients and hospital staff are described previously.^{19,22}

In the same procedure as the ¹²⁵I seed localization in the axillary lymph node, a ¹²⁵I seed was placed in the breast tumor, which

is in our institute standard practice for patients undergoing NST. Afterward, a conventional radiography was performed to confirm the presence of the ¹²⁵I seed in the axilla and in the breast.

Surgical Procedure

After completion of NST, surgery of the breast and the axilla was executed in the same session. One of 8 different surgeons performed the procedure. The surgical part of the MARI procedure has been described before in detail.²⁰ In short, with the γ -probe (neo2000, Neoprobe Corporation, Dublin, OH) on the ¹²⁵I setting, the point of greatest activity was detected on the skin of the axilla. The incision to remove the MARI node was made in the planned incision for the ALND, close to the point of highest activity. Guided by the γ -probe, the MARI node was intraoperatively detected and selectively removed (Fig. 1C). Removal of the correct lymph node was ensured by detecting the ¹²⁵I source of radioactivity within the lymph node *ex vivo* and by detecting the absence of radiation in the axilla within the area of the excision. After removal of the MARI node, an ALND was performed in all patients and consequently, surgery to the breast was performed.

Pathology Examination

The pathologist extracted the ¹²⁵I seed from the MARI node using a γ -radiation detector. After removal of the seed, the MARI node was bisected and completely embedded. All paraffin blocks were cut at 3 levels with minimal 150- μ m intervals. The MARI node was assessed according to the routine pathological assessment in SNB procedure. H&E staining was performed in all cases. Immunohistochemical keratin staining was done only in lymph nodes with a tumor-negative hematoxylin and eosin (H&E) staining. Lymph nodes in the axillary dissection specimen were evaluated at 1 level and stained with H&E; immunohistochemical staining was not routinely performed. A specialized breast cancer pathologist (J.W.) revised all MARI nodes and classified them according to the response to the systemic treatment. For this study, pathologic complete response was defined as no vital tumor cells present in the lymph node, irrespectively of the response in the breast.

Statistical Analysis

The primary endpoints used for statistical analysis were the success rate for identifying and selectively removing the MARI node and the correlation of the response observed in the MARI node on pathology with the ALND specimen.

To calculate the sample size needed for the prediction model of response of the axilla, we hypothesized that the expected true-positive rate for the localization method would be 95% and that the observed true positive rate will be above a minimally acceptable limit of 90%, with a 1-sided 95% confidence interval (CI). Based on these hypotheses, 52 patients with residual vital tumor cells in the MARI node after NST were required to assess the correlation of the response observed in the MARI node with the response observed in the ALND specimen.

The identification rate of the MARI node was analyzed in all patients who underwent surgical removal of the MARI node. Correlation between the pathologic response observed in the MARI node and in the ALND specimen was estimated using false-negative rates, sensitivity, specificity, positive predictive value, negative predictive value, and accuracy.

RESULTS

Patient Characteristics and Seed Localization

Table 1 illustrates patient and tumor characteristics of the 103 patients before the systemic treatment. The median age at the time of

TABLE 1. Patient- and Tumor-related Characteristics (n = 103)

Median Age in Years (Range)	49 (24–67)
Radiological tumor stage before systemic treatment	
T0	1 (1%)
T1	24 (23%)
T2	51 (50%)
T3	20 (19%)
T4	7 (7%)
Clinical lymph node stage before systemic treatment	
N1	62 (60%)
N2	13 (13%)
N3	28 (27%)
Tumor histopathology	
Ductal carcinoma	88 (85%)
Lobular carcinoma	8 (8%)
Adenocarcinoma NOS	7 (7%)
Receptor-based subtype*	
ER-/PgR-/Her2-	22 (21%)
ER+/Her2-	54 (52%)
Her2+	27 (26%)
Neoadjuvant systemic treatment regimen	
ddAC†	72 (70%)
CD‡	3 (3%)
PTC§	24 (23%)
Other	4 (4%)

*Receptor-based subtype as established on histological biopsy before neoadjuvant systemic treatment.

†Doxorubicine 60 mg/m² and cyclophosphamide 600 mg/m² q 2 wk \times 6.

‡Docetaxel 75 mg/m² and capecitabine 2 \times dd 1000 mg/m² orally during 14 d, q 3 wk \times 6

§Paclitaxel 70 mg/m², trastuzumab 2 mg/m², and carboplatin 3 AUC mg/mL/min on days 1, 8, 15, 22, 29, 35 q 8 wk \times 3.

ER indicates estrogen receptor; Her2, human epidermal growth factor receptor; PgR, progesterone receptor.

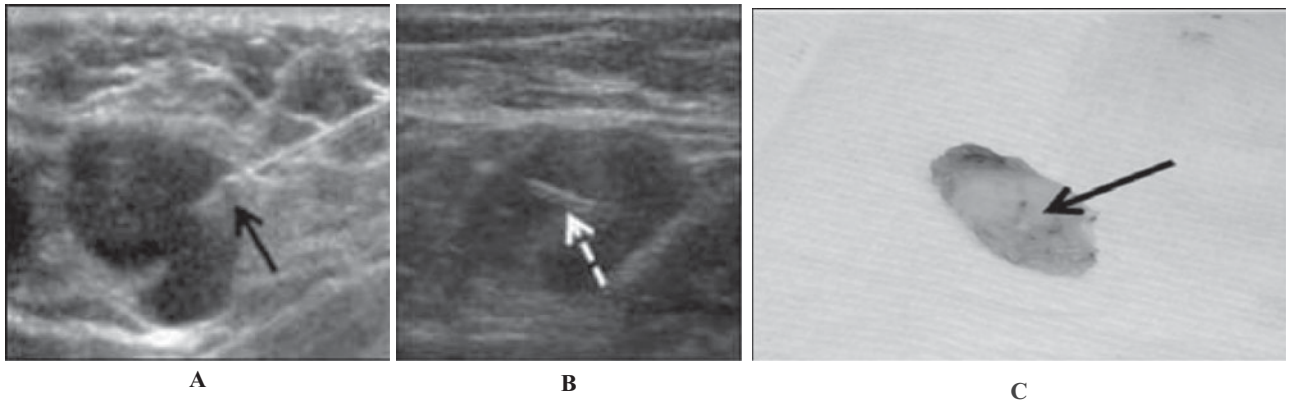


FIGURE 1. A, Insertion of a radioactive iodine seed in an axillary lymph node under ultrasound guidance. The black arrow indicates the tip of an 18-G needle through which the iodine seed is inserted in the lymph node. B, Position of the iodine seed in the lymph node. C, Excised lymph node with the iodine seed in situ.

enrollment was 49 years (range: 24–67 years) and most patients had a T1 or T2 tumor. The majority of the patients (85%) had an invasive ductal carcinoma, and 52% of the patients were estrogen receptor positive.

In all patients, an attempt was made to mark 1 proven pathological axillary lymph node. No complication occurred during the ultrasound-guided positioning of the ¹²⁵I seed. In 2 patients, the seed could not be properly positioned in the lymph node.

Surgical Procedure and Identification Rate of the MARI Node

In 3 of the 103 patients, selective surgical removal of the MARI node was not attempted because of the presence of distant metastasis before surgery (n = 2) or switch to primary surgery (n = 1) (Fig. 2). The resulting 100 patients underwent the surgical part of the MARI procedure. At the time of surgery, the ¹²⁵I seed had been in place for a median of 17 weeks (range: 9–31 weeks) and had an apparent activity varying from 0.006 to 0.06 mCi (0.2–2.1 MBq). All seeds could be easily detected using the γ -probe. The median time of the identification and excision of the MARI node was 6 minutes (range: 3–20 minutes). In all 100 patients, the ¹²⁵I seed was identified and removed during surgery. In 3 patients, the MARI node could not be identified because the ¹²⁵I seed was not properly located into a lymph node. This resulted in an identification rate of the MARI node of 97% (97 of 100 patients; 95% CI: 91–99). In 2 of these 3 patients with nonidentification, misplacement of the seed had occurred during the radiological localization procedure. In the third patient, a reason for the presence of the seed outside the lymph node was not found. A complementary ALND was not performed in 2 patients because of the presence of distant metastasis (n = 1) and patient’s refusal (n = 1). Thus, the correlation between response in the MARI node and the additional lymph nodes could be assessed in 95 patients.

Accuracy of the MARI Node

Overall, the NST resulted in a pathologic complete response of all axillary lymph nodes (MARI node + additional nodes) of 26% (25/95).

The correlation between the response in MARI node and the response in the additional lymph nodes is presented in Table 2. The MARI node was tumor-positive in 65 patients. Additional positive nodes in the ALND specimen were found in 46 of these 65 patients

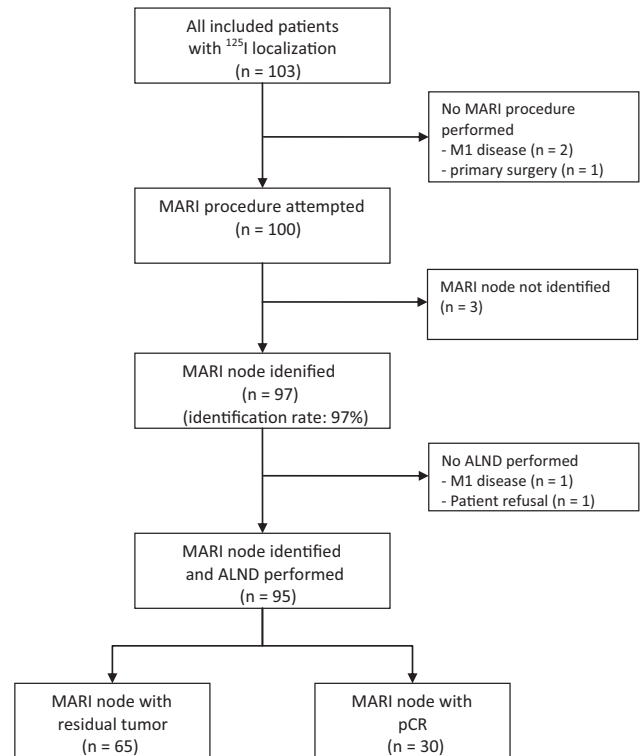


FIGURE 2. Flowchart for all included patients. ¹²⁵I indicates radioactive iodine seed; pCR, complete pathological response.

(71%). The median number of positive additional nodes was 3 (range: 1–28).

In the remaining 30 patients with a negative MARI node, residual disease in the additional lymph nodes was found in 5 patients (negative-predicting value: 83%; 95% CI: 65–94). Of these 5 patients, the additional nodes contained only isolated tumor cells in 2 patients and a macrometastasis in 3 patients.

The MARI node accurately predicted axillary nodal status after NST in 90 of the 95 patients (overall accuracy: 95%; 95% CI: 88–95).

TABLE 2. Pathologic Results of the MARI Node and Additional Axillary Lymph Nodes in Patients in Whom the MARI Node Was Identified (n = 95)*

	Outcome Additional Lymph Nodes		Total
	Positive	Negative	
Outcome MARI node			
Positive	46	19	65
Negative	5	25	30
Total	51	44	95

*False negative rate: 5/70 = 7% (95% CI: 2–16); overall accuracy: 90/95 = 95% (95% CI: 88–95); negative predicting value: 25/30 = 83% (95% CI: 65–94); positive predicting value: 100% (by definition); sensitivity: 46/51 = 90% (95% CI: 79–97); specificity: 100% (by definition).

The false-negative rate of the MARI procedure was 5 of 70 = 7% (95% CI: 2–16).

DISCUSSION

The MARI procedure (Marking Axillary Lymph Nodes With Radioactive Iodine Seeds) has a high identification rate of 97% and a low false-negative rate of 7%. It is safe, feasible, and promising as a new technique to assess axillary lymph node involvement after NST. This study is the first to investigate the use of ¹²⁵I seeds to mark positive lymph nodes before the start of NST and selectively removing them afterward.

Another more common method used to assess axillary lymph node involvement after NST is the postchemotherapy SNB. Currently, this method in patients who present with metastatic lymph nodes before the start of NST is debated, because different results regarding identification rates and false-negative rates are reported.^{8,14} Recently, 2 large prospective, multicenter trials investigated the role of the SNB after NST: the ASOCOS Z1071 trial and the German SENTINA trial. The ACOSOG Z1071 trial was designed to evaluate SNB after NST in patients with clinical T0–4, N1–2, M0 breast cancer. With an accrual of 756 patients, the identification rate was 93%, the accuracy was 84%, and the false-negative rate was 13% in patients with pre-chemo cN1 disease and 2 or more SNs reviewed.²³ The SENTINA trial is a 4-arm trial evaluating the timing of the SNB in patients undergoing NST.²⁴ The identification rate of the SN in patients who converted from cN1 prechemo to cN0 after the chemotherapy was 80% (474/595) and the false-negative rate was 14%. They concluded that post-chemo SNB as a diagnostic procedure is not a reliable tool in patients who are clinically node-positive before the systemic treatment.

The identification rate and the false-negative rate of the MARI procedure seem favorable compared with results of the postchemotherapy SNB in patients presenting with node-positive breast cancer. The high false-negative rate of the SNB after systemic treatment may be caused by residual tumor cells obstructing the lymphatic channels or altering lymphatic flow. This disadvantage does not exist in the MARI procedure, because the identification of the affected lymph node is independent of changes in lymphatic flow due to treatment.

The MARI procedure is a safe technique and easy to learn. Radiological insertion can be challenging if the node is small, and, therefore, confirmation of the localization with ultrasound is necessary. Surgical removal of the MARI node requires skills comparable with the removal of an SN. The surgeons performing the MARI procedure in our institute found the technique even easier than removing an SN, because there was no background radiation.

A few limitations of the MARI procedure were identified and modified. First, because the fine-needle aspiration was performed in

a separate intervention from the seed localization, it is very important to document the localization of the pathological lymph node to avoid seed localization in a tumor-negative lymph node. Repeating fine-needle aspiration of the node after insertion could confirm localization in the correct node. Second, ultrasound-guided localization of the seed in a small lymph node can be difficult, as was illustrated by the 2 patients in whom the seed was not properly located in the lymph node. Therefore, training of the radiologists and confirmation of the location of the seed by ultrasonography is very important. Third, the iodine seed is—however minimal—radioactive and can in theory itself sterilize tumor-positive lymph nodes. We lowered the radiation dose to such an extent that any radiation effect to the lymph node was minimized without the seed getting untraceable. Finally, the iodine seed is a radioactive source, and although the dose of these iodine seeds is low, it requires authorization by the government and safety issues need to be addressed. However, when safety protocols are taken into account, the iodine seed is an easy and patient-friendly localization method. Marking of the axillary lymph node was performed in the same procedure as marking of the breast lesion, so no separate visit had to be scheduled. Furthermore, because the half-life time of the iodine seed is 60 days, there is no strict time frame in which the ¹²⁵I seeds have to be placed. This is in contrast with the SNB in which radiocolloid is injected, where the half-life is about 8 hours. Therefore, the injection of the radiocolloid has to be given 1 day before or at the same day of surgery, and it may cause scheduling conflicts.

With an identification rate of 97% and false-negative rate of 7%, the MARI procedure is a reliable measurement of the axillary response and may be used to tailor further axillary treatment after neoadjuvant systemic treatment. How to treat the axilla after a negative MARI node is yet undetermined. Theoretically, the axilla can be left untreated when all nodal metastases responded completely to systemic therapy. In primary breast surgery, there is even trend toward omitting axillary treatment in patients with a positive SN, because some studies showed no survival benefit of ALND.^{25,26} Furthermore, it has been shown that axillary radiotherapy in patients with primary breast surgery and a positive SNB gives the same rates of axillary recurrences and survival compared with ALND, with less side effects.²⁷ Therefore, axillary radiotherapy could be a good option in these patients. Whether axillary treatment can be completely omitted in patients with a tumor-negative MARI node will be subject of future research.

CONCLUSIONS

It is technically possible to mark tumor-positive axillary lymph nodes with an iodine seed before the start of the NST and selectively remove them afterward. The MARI procedure is a safe and patient-friendly method with a high identification rate and low false-negative rate. We believe that this method can be used to select patients with a complete pathological response in the axillary lymph nodes and omit an ALND in these patients.

ACKNOWLEDGMENTS

The authors thank J. van Zijl-de Jong, M. J. Holtkamp, J. Fokkema, I. Kemper, and V. van Hout for patients accrual and patient care; H. Maessen, M. Steggerda, L. Janssen, and S. Muller for their advice regarding physics and radiation protection; H. S. A Oldenburg and J. A. van der Hage for surgery; and the staff of the department of Radiology for marking the lymph nodes.

REFERENCES

1. Mieog JS, van der Hage JA, van de Velde CJ. Neoadjuvant chemotherapy for operable breast cancer. *Br J Surg*. 2007;94:1189–1200.

2. Alm El-Din MA, Taghian AG. Breast conservation therapy for patients with locally advanced breast cancer. *Semin Radiat Oncol*. 2009;19:229–235.
3. Beriwal S, Schwartz GF, Komarnicky L, et al. Breast-conserving therapy after neoadjuvant chemotherapy: long-term results. *Breast J*. 2006;12:159–164.
4. Loo CE, Straver ME, Rodenhuis S, et al. Magnetic resonance imaging response monitoring of breast cancer during neoadjuvant chemotherapy: relevance of breast cancer subtype. *J Clin Oncol*. 2011;29:660–666.
5. Loo CE, Teertstra HJ, Rodenhuis S, et al. Dynamic contrast-enhanced MRI for prediction of breast cancer response to neoadjuvant chemotherapy: initial results. *AJR Am J Roentgenol*. 2008;191:1331–1338.
6. Specht J, Gralow JR. Neoadjuvant chemotherapy for locally advanced breast cancer. *Semin Radiat Oncol*. 2009;19:222–228.
7. Kuerer HM, Newman LA, Fornage BD, et al. Role of axillary lymph node dissection after tumor downstaging with induction chemotherapy for locally advanced breast cancer. *Ann Surg Oncol*. 1998;5:673–680.
8. Alvarado R, Yi M, Le Petross H, et al. The role for sentinel lymph node dissection after neoadjuvant chemotherapy in patients who present with node-positive breast cancer. *Ann Surg Oncol*. 2012;19:3177–3184.
9. Wang Z, Wu LC, Chen JQ. Sentinel lymph node biopsy compared with axillary lymph node dissection in early breast cancer: a meta-analysis. *Breast Cancer Res Treat*. 2011;129:675–689.
10. Levangie PK, Drouin J. Magnitude of late effects of breast cancer treatments on shoulder function: a systematic review. *Breast Cancer Res Treat*. 2009;116:1–15.
11. Wang Y, Zhang C, Liu J, et al. Is 18F-FDG PET accurate to predict neoadjuvant therapy response in breast cancer? A meta-analysis. *Breast Cancer Res Treat*. 2012;131:357–369.
12. Rousseau C, Devillers A, Campone M, et al. FDG PET evaluation of early axillary lymph node response to neoadjuvant chemotherapy in stage II and III breast cancer patients. *Eur J Nucl Med Mol Imaging*. 2011;38:1029–1036.
13. Hieken TJ, Boughey JC, Jones KN, et al. Imaging response and residual metastatic axillary lymph node disease after neoadjuvant chemotherapy for primary breast cancer. *Ann Surg Oncol*. 2013;20:3199–3204.
14. van Deurzen CH, Vriens BE, Tjan-Heijnen VC, et al. Accuracy of sentinel node biopsy after neoadjuvant chemotherapy in breast cancer patients: a systematic review. *Eur J Cancer*. 2009;45:3124–3130.
15. Fontein DB, van de Water W, Mieog JS, et al. Timing of the sentinel lymph node biopsy in breast cancer patients receiving neoadjuvant therapy—recommendations for clinical guidance. *Eur J Surg Oncol*. 2013;39:417–424.
16. Gray RJ, Salud C, Nguyen K, et al. Randomized prospective evaluation of a novel technique for biopsy or lumpectomy of nonpalpable breast lesions: radioactive seed versus wire localization. *Ann Surg Oncol*. 2001;8:711–715.
17. Jakub JW, Gray RJ, Degnim AC, et al. Current status of radioactive seed for localization of non palpable breast lesions. *Am J Surg*. 2010;199:522–528.
18. van Riet YE, Maaskant AJ, Creemers GJ, et al. Identification of residual breast tumour localization after neo-adjuvant chemotherapy using a radioactive 125 Iodine seed. *Eur J Surg Oncol*. 2010;36:164–169.
19. Donker M, Drukker CA, Valdes Olmos RA, et al. Guiding breast-conserving surgery in patients after neoadjuvant systemic therapy for breast cancer: a comparison of radioactive seed localization with the ROLL technique. *Ann Surg Oncol*. 2013;20:2569–2575.
20. Straver ME, Loo CE, Alderliesten T, et al. Marking the axilla with radioactive iodine seeds (MARI procedure) may reduce the need for axillary dissection after neoadjuvant chemotherapy for breast cancer. *Br J Surg*. 2010;97:1226–1231.
21. Hannemann J, Oosterkamp HM, Bosch CA, et al. Changes in gene expression associated with response to neoadjuvant chemotherapy in breast cancer. *J Clin Oncol*. 2005;23:3331–3342.
22. Alderliesten T, Loo CE, Pengel KE, et al. Radioactive seed localization of breast lesions: an adequate localization method without seed migration. *Breast J*. 2011;17:594–601.
23. Boughey JC, Suman VJ, Mittendorf EA, et al. Sentinel lymph node surgery after neoadjuvant chemotherapy in patients with node-positive breast cancer: the ACOSOG Z1071 (Alliance) clinical trial. *JAMA*. 2013;310:1455–1461.
24. Kuehn T, Bauerfeind I, Fehm T, et al. Sentinel-lymph-node biopsy in patients with breast cancer before and after neoadjuvant chemotherapy (SENTINA): a prospective, multicentre cohort study. *Lancet Oncol*. 2013;14:609–618.
25. Giuliano AE, Hunt KK, Ballman KV, et al. Axillary dissection vs no axillary dissection in women with invasive breast cancer and sentinel node metastasis: a randomized clinical trial. *JAMA*. 2011;305:569–575.
26. Galimberti V, Cole BF, Zurrada S, et al. Axillary dissection versus no axillary dissection in patients with sentinel-node micrometastases (IBCSG 23-01): a phase 3 randomised controlled trial. *Lancet Oncol*. 2013;14:297–305.
27. Rutgers E, Donker M, Straver ME, et al. Radiotherapy or surgery of the axilla after a positive sentinel node in breast cancer patients: final analysis of the EORTC AMAROS trial (10981/22023). *J Clin Oncol*. 2013;31(suppl):abstr LBA1001.